

## Original Research Article

# MICROSCOPIC AGREEMENT: REASSESSING FNAC ACCURACY THROUGH POSTOPERATIVE HISTOLOGICAL CROSS-MAPPING IN THYROID LESIONS

Radhika Nalliah<sup>1</sup>, G Kanimozhi<sup>2</sup>, Meera Balakrishnan<sup>3</sup>, Srinath Ramamurthy<sup>4</sup>

<sup>1</sup>Associate Professor, Department of Pathology, Sri Venkateswara Medical college and Research Institute, (Sri Venkateswara Medcity), Nallur, Tamil Nadu, India.

<sup>2</sup>Associate Professor, Department of Pathology, Shri Sathya Sai Medical College and Research Institute, Ammapettai, Tamil Nadu, India.

<sup>3</sup>Associate Professor, Department of Pathology, Swamy Vivekananda Medical College Hospital and Research Institute, Tiruchengode, Tamil Nadu, India.

<sup>4</sup>Associate Professor, Department of Community Medicine, Shri Sathya Sai Medical College and Research Institute, Ammapettai, Tamil Nadu, India.

Received : 11/04/2025  
Received in revised form : 29/05/2025  
Accepted : 17/06/2025

## Corresponding Author:

**Dr. Srinath Ramamurthy,**  
Associate Professor, Department of  
Community Medicine, Shri Sathya Sai  
Medical College and Research Institute,  
Ammappettai, Tamil Nadu, India.  
Email: ram.srinath22@gmail.com

DOI: 10.70034/ijmedph.2025.2.489

Source of Support: Nil,  
Conflict of Interest: None declared

Int J Med Pub Health  
2025; 15 (2); 2701-2704

## ABSTRACT

**Background:** Fine-needle aspiration cytology (FNAC) is a key diagnostic approach in the initial assessment of thyroid nodules. It offers a safe, minimally invasive, and rapid method for cytological evaluation. However, its diagnostic precision can differ among clinical settings. This study was undertaken to evaluate the accuracy of FNAC by correlating its findings with those from definitive histopathological examination.

**Materials and Methods:** A prospective observational study was carried out on 100 patients with thyroid swellings who had undergone FNAC followed by thyroidectomy were enrolled. Findings were divided using the Bethesda System. Final histopathological diagnoses were used as the reference standard.

**Results:** Among the 100 patients, histopathology confirmed 68 benign and 32 malignant cases. FNAC demonstrated a sensitivity of 90.6%, specificity of 95.5%, positive predictive value of 90.6%, and negative predictive value of 95.5%. The diagnostic accuracy was 93%, with a kappa coefficient of 0.86, indicating excellent agreement. Colloid goitre was the predominant benign lesion, while papillary carcinoma was the most frequent malignancy.

**Conclusion:** FNAC remains a dependable, accurate method for evaluating thyroid nodules. When interpreted systematically and correlated with histopathology, it plays a crucial role in guiding management.

**Keywords:** Thyroid nodules, Cytology, Fine-needle aspiration, Histological correlation, Bethesda classification, Diagnostic performance.

## INTRODUCTION

Thyroid nodules are observed in 4–7% of individuals on physical examination, and in over half the population when assessed with high-resolution ultrasonography.<sup>[1]</sup> While the majority of these nodules are non-malignant, a small but clinically significant subset can harbor thyroid cancer, necessitating timely and accurate diagnostic evaluation.<sup>[2]</sup> Among the available diagnostic modalities, fine-needle aspiration cytology (FNAC) has established itself as the primary initial

investigation due to its simplicity, affordability, and minimally invasive nature.<sup>[3]</sup>

Since its introduction in the mid-20th century, FNAC has become integral in the diagnostic workflow of thyroid nodules. It enables cytomorphological categorization that facilitates differentiation between benign and malignant lesions, potentially reducing the need for surgical intervention in low-risk cases.<sup>[4]</sup> The Bethesda System for Reporting Thyroid Cytopathology (TBSRTC) was developed to bring uniformity to FNAC interpretation and reporting, classifying results into six diagnostic categories that

correspond with specific risk levels and management protocols.<sup>[5]</sup>

Despite its widespread acceptance, FNAC has limitations, particularly in cases yielding indeterminate or suspicious results. The diagnostic accuracy of FNAC varies based on multiple factors including aspirate quality, nodule characteristics, and pathologist expertise.<sup>[6]</sup> Moreover, follicular neoplasms often pose diagnostic challenges because FNAC cannot reliably evaluate capsular or vascular invasion—features essential for distinguishing follicular adenoma from carcinoma.<sup>[7]</sup>

Histopathological examination following surgical excision remains the definitive method for establishing a conclusive diagnosis, offering architectural and invasive features not accessible through cytological sampling.<sup>[8]</sup> Consequently, comparing FNAC findings with postoperative histology is critical for validating its diagnostic precision and refining clinical management strategies.

Numerous studies have attempted to quantify the diagnostic indices of FNAC, including sensitivity, specificity, and accuracy, often yielding variable results. These discrepancies reflect institutional differences in technique, interpretation, and patient profiles, highlighting the need for local data to support evidence-based decisions.<sup>[9]</sup>

In clinical settings, especially where resources are constrained, FNAC continues to serve as a frontline diagnostic tool. Evaluating its concordance with histopathology is therefore essential to ensure accurate diagnosis, minimize unnecessary surgeries, and improve early cancer detection.

This study was designed to assess the diagnostic reliability of FNAC in evaluating thyroid lesions by comparing cytological interpretations with histopathological outcomes from surgically resected thyroid tissues, focusing on its sensitivity, specificity, and predictive accuracy.

## MATERIALS AND METHODS

This cross-sectional observational study was done over a span of 12-month period from March 2024 to February 2025 Department of Pathology, at tertiary care hospital. The primary objective was to assess the diagnostic reliability of fine-needle aspiration cytology (FNAC) in thyroid lesions by comparing cytologic findings with subsequent histopathological diagnoses obtained from surgically excised specimens.

Patients presenting with thyroid nodules who underwent FNAC as part of their diagnostic workup

were considered eligible. Only those who subsequently underwent thyroidectomy, with complete histopathology results available, were included for final analysis. Patients whose cytological samples were inadequate or who did not undergo surgery were excluded. Sampling was performed on a consecutive basis, including all qualifying patients during the designated study period.

### Inclusion Criteria

- Patients with thyroid swellings who underwent FNAC and surgery.
- Availability of complete histopathological reports post-resection.

### Exclusion Criteria

- Inadequate or non-diagnostic FNAC smears.
- Patients who did not proceed to thyroidectomy.
- Incomplete or missing histopathological data.

FNAC was conducted using a 22–25 gauge needle, employing standard aseptic techniques. In most cases, the procedure was performed without imaging guidance. Multiple passes were taken per nodule, and aspirated material was immediately smeared onto clean glass slides. Air-dried smears were stained with May-Grünwald-Giemsa, while alcohol-fixed preparations were processed using hematoxylin and eosin (H&E) and Papanicolaou stains. Cytological diagnoses were assigned based on the Bethesda System for Reporting Thyroid Cytopathology (TBSRTC), with each case categorized into one of six diagnostic categories.

Thyroidectomy specimens were examined macroscopically and processed via formalin fixation, paraffin embedding, sectioning, and hematoxylin-eosin staining. Final histopathological diagnoses were made following the World Health Organization (WHO) classification of thyroid neoplasms, and cases were broadly grouped as benign or malignant. All data were compiled and analyzed using IBM SPSS Statistics version 25.0. The effectiveness of FNAC in diagnosing thyroid lesions was evaluated by comparing cytologic results against histopathology, considered the definitive standard. Key metrics calculated included sensitivity, specificity, positive predictive value (PPV), negative predictive value (NPV), and overall accuracy. Associations were deemed statistically significant at a p-value threshold of <0.05. Additionally, Cohen's kappa coefficient was used to measure the level of correlation between FNAC and histopathological outcomes.

Ethical clearance was obtained from the Institutional Ethics Committee prior to initiating the study. All participants provided written informed consent, and patient confidentiality was upheld throughout the research process.

## RESULTS

**Table 1: Demographic Profile of Study Participants.**

Variable	Value
Total cases	100
Mean age (years)	42.6

Age range (years)	18–72
Males	28
Females	72
Patients < 30 years	18
Patients 30–50 years	54
Patients > 50 years	28

**Table 2: FNAC Categorization According to Bethesda System**

Bethesda Category	No. of patients	Malignancy Risk (%)
I. Non-diagnostic	6 (6%)	N/A
II. Benign	54 (54%)	0–3%
III. Atypia of Undetermined Significance	12 (12%)	5–15%
IV. Follicular Neoplasm/Suspicious for FN	10 (10%)	15–30%
V. Suspicious for Malignancy	8 (8%)	60–75%
VI. Malignant	10 (10%)	97–99%

**Table 3: Histopathological Subtypes of Thyroid Lesions**

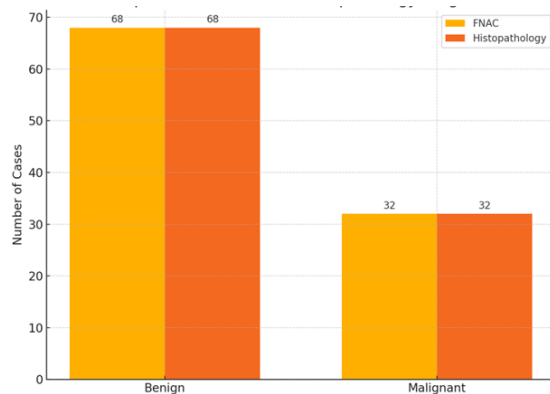
Histopathological Diagnosis	Number of Cases	Percentage (%)
Colloid goitre	38	38%
Thyroiditis (Hashimoto/Subacute)	18	18%
Follicular adenoma	12	12%
Papillary carcinoma	22	22%
Follicular carcinoma	6	6%
Medullary carcinoma	4	4%

**Table 4: Correlation Between FNAC and Histopathology**

FNAC Result	Histologically Benign	Histologically Malignant	Total
Benign	65	3	68
Malignant	3	29	32

**Table 5: Diagnostic Indices of FNAC with 95% Confidence Intervals**

Diagnostic Measure	Value	95% Confidence Interval
Sensitivity	90.6%	76.9% – 97.3%
Specificity	95.5%	87.5% – 99.1%
Positive Predictive Value (PPV)	90.6%	76.9% – 97.3%
Negative Predictive Value (NPV)	95.5%	87.5% – 99.1%
Overall Diagnostic Accuracy	93%	86% – 97%
Cohen’s Kappa Coefficient	0.86	—



**Figure 1: Comparison of FNAC and HPE diagnostic findings.**

Among the 100 patients included in the study, the average age was 42.6 years, with the age group of 30–50 years representing the majority (54%). The gender distribution showed a higher prevalence in females (72%) compared to males (28%).

Fine-needle aspiration cytology (FNAC) results, classified using the Bethesda System, revealed that most lesions (54%) were benign (Category II). Categories III, IV, V, and VI represented 12%, 10%, 8%, and 10% of cases, respectively, while 6% were non-diagnostic (Category I).

Histopathological examination of surgical specimens confirmed 68 benign and 32 malignant cases. Among benign diagnoses, colloid goitre was the most common (38%), followed by thyroiditis (18%) and follicular adenoma (12%). The predominant malignancy was papillary carcinoma (22%), with follicular carcinoma and medullary carcinoma comprising 6% and 4%, respectively.

A direct comparison between FNAC and histopathological findings showed that 65 of 68 benign cytology results matched the final benign diagnosis, while 29 of 32 malignant cytology results corresponded to confirmed malignancies. There were three discrepancies in each category—false negatives and false positives.

Performance metrics revealed that FNAC achieved a sensitivity of 90.6%, specificity of 95.5%, positive predictive value (PPV) of 90.6%, and negative predictive value (NPV) of 95.5%. The overall diagnostic accuracy was 93%, and the Cohen’s kappa coefficient was 0.86, indicating strong concordance between cytological and histological assessments. Confidence intervals were also robust, with sensitivity ranging from 76.9% to 97.3% and specificity from 87.5% to 99.1%.

These results reaffirm the diagnostic utility of FNAC in evaluating thyroid lesions, offering high.

## DISCUSSION

The identification and differentiation of benign and malignant thyroid nodules remain critical to ensuring appropriate treatment decisions and minimizing avoidable surgical interventions. Fine-needle aspiration cytology (FNAC) continues to play a key role in the diagnostic evaluation of thyroid swellings, owing to its minimally invasive nature and high clinical utility. This study was conducted to evaluate the effectiveness of FNAC by comparing its results with those of postoperative histopathological examination.

In our analysis, FNAC demonstrated a sensitivity of 90.6%, specificity of 95.5%, positive predictive value of 90.6%, negative predictive value of 95.5%, and an overall diagnostic accuracy of 93%. These findings are consistent with established evidence. A large meta-analysis conducted by Bongiovanni et al. reported an average sensitivity of 91% and specificity of 96% for thyroid FNAC, aligning closely with our results.<sup>[10]</sup> Likewise, Yang et al. examined 4,703 cases and observed a sensitivity of 89% and specificity of 98%, reinforcing the reliability of FNAC in identifying thyroid malignancies.<sup>[11]</sup>

The diagnostic agreement between cytological and histopathological findings in our study was also strong, as reflected by a Cohen's kappa coefficient of 0.86, suggesting substantial inter-method agreement. This reinforces the value of the Bethesda System, which has standardized FNAC reporting and reduced diagnostic ambiguity, as noted by Cibas and Ali.<sup>[12]</sup> Among malignant lesions confirmed on histopathology, papillary carcinoma was most frequently encountered (22%), consistent with global trends where it represents the most prevalent form of thyroid cancer.<sup>[13]</sup> However, our proportion was relatively lower than expected, potentially reflecting regional variation or sample size-related limitations. Despite the high diagnostic performance, FNAC was not without limitations. In three cases, FNAC misclassified malignant nodules as benign, possibly due to overlapping features in follicular-patterned lesions or suboptimal sampling. Similarly, three benign lesions were overinterpreted as malignant, which may occur in hyperplastic nodules with cytological atypia. Such discrepancies highlight the importance of cautious interpretation, particularly in categories with intermediate cytologic features.

Clinically, the high negative predictive value of 95.5% underscores FNAC's value in excluding malignancy, helping to avoid unnecessary thyroidectomies in benign conditions. However, categories III, IV, and V remain diagnostically challenging, often necessitating supplementary tools such as molecular diagnostics or repeat sampling.<sup>[14]</sup> The single-center design and relatively small sample size are acknowledged limitations that may affect the general applicability of the findings. Additionally,

observer variation, although minimized, cannot be completely ruled out.

Moving forward, integrating FNAC findings with molecular markers, radiological characteristics, and risk stratification systems could enhance the diagnostic yield, especially for indeterminate nodules.

## CONCLUSION

This study confirms that fine-needle aspiration cytology (FNAC) is a precise, less invasive diagnostic tool for evaluating thyroid lesions. It is particularly effective in excluding malignancy, thereby reducing unnecessary surgical interventions. However, challenges remain in interpreting indeterminate categories, warranting adjunct diagnostic methods. Incorporating FNAC into a multidisciplinary approach enhances clinical decision-making. Continuous evaluation and refinement of cytological techniques are essential to maintain diagnostic precision and improve patient outcomes in thyroid pathology.

**Acknowledgement:** The authors would like to acknowledge the efforts put in by the departmental staff for this study

## REFERENCES

1. Hegedüs L. Clinical practice. The thyroid nodule. *N Engl J Med*. 2004;351(17):1764–71.
2. Ross DS, Burch HB, Cooper DS, Greenlee MC, Laurberg P, Maia AL, et al. 2015 American Thyroid Association guidelines for diagnosis and management of thyroid nodules. *Thyroid*. 2015;25(1):1–63.
3. Gharib H, Papini E, Garber JR, Duick DS, Harrell RM, Hegedüs L, et al. American Association of Clinical Endocrinologists and Associazione Medici Endocrinologi Guidelines for thyroid nodules. *Endocr Pract*. 2016;22(5):622–39.
4. VanderLaan PA, Marqusee E, Krane JF. Clinical significance of non-diagnostic thyroid fine-needle aspirations. *Cancer Cytopathol*. 2011;119(3):186–94.
5. Cibas ES, Ali SZ. The Bethesda System for Reporting Thyroid Cytopathology. *Thyroid*. 2009;19(11):1159–65.
6. Bongiovanni M, Spitale A, Faquin WC, Mazzucchelli L, Baloch ZW. The Bethesda System for Reporting Thyroid Cytopathology: A meta-analysis. *Acta Cytol*. 2012;56(4):333–9.
7. Baloch ZW, LiVolsi VA. Follicular-patterned lesions of the thyroid: the bane of the pathologist. *Am J Clin Pathol*. 2002;117(1):143–50.
8. Lloyd RV, Osamura RY, Klöppel G, Rosai J, editors. WHO Classification of Tumours of Endocrine Organs. 4th ed. Lyon: IARC Press; 2017.
9. Yang J, Schnadig V, Logrono R, Wasserman PG. Fine-needle aspiration of thyroid nodules: a study of 4,703 patients with histologic and clinical correlation. *Cancer*. 2007;111(5):306–15.
10. Bongiovanni M, Spitale A, Faquin WC, Mazzucchelli L, Baloch ZW. The Bethesda System for Reporting Thyroid Cytopathology: A meta-analysis. *Acta Cytol*. 2012;56(4):333–9.
11. Yang J, Schnadig V, Logrono R, Wasserman PG. Fine-needle aspiration of thyroid nodules: a study of 4,703 patients with histologic and clinical correlation. *Cancer*. 2007;111(5):306–15.
12. Cibas ES, Ali SZ. The Bethesda System for Reporting Thyroid Cytopathology. *Thyroid*. 2009;19(11):1159–65.
13. Lloyd RV, Osamura RY, Klöppel G, Rosai J, editors. WHO Classification of Tumours of Endocrine Organs. 4th ed. Lyon: IARC Press; 2017.
14. Haugen BR, Alexander EK, Bible KC, Doherty GM, Mandel SJ, Nikiforov YE, et al. 2015 American Thyroid Association management guidelines for adult patients with thyroid nodules and differentiated thyroid cancer. *Thyroid*. 2016;26(1):1–133.